

VLU treatment guide*

1. Cleanse and debride

Select a gentleskin cleanser with a pH close to that of the skin to clean the wound bed and surrounding skin. Debride the wound if required. Remove slough and devitalized tissue including dry skin. Follow your local policy.

2. Dress the wound

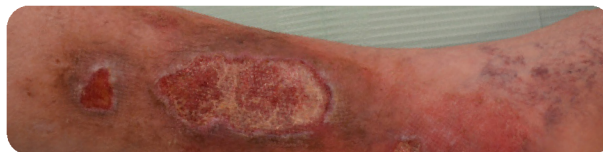Choose a dressing with a silicone interface to protect the wound and the surrounding skin, while effectively absorbing exudate.

Is the wound infected?

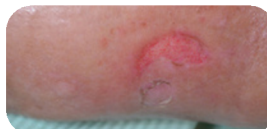Antimicrobial dressings may be used for a short period to manage wound infections. If there is concern that the wound is infected, consult local protocols or seek guidance from a specialist nurse.

Exudate level

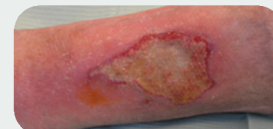For moderate to high exudate, use foam dressings. For higher levels of exudate, consider a combination of products such as wound contact layer and superabsorbent dressings.



Not infected



Infected



Mepilex® Up




Mepitel®

+




Mextra® Superabsorbent



Exufiber® Ag

+



Mepilex® Up

3. Moisturise

Apply a basic emollient to restore skin hydration.

4. Compress

Compression therapy to improve healing and prevent recurrences.

Engage your patient

Encourage your patients to stay active and mobile, and offer advice on nutrition and healthy life style.



Safetac® technology. Less damage. Less pain. Dressings with Safetac® are clinically demonstrated to minimise damage to the wound and skin at removal¹⁻⁸. Pain at dressing change is minimised^{1-6,9}.



Scan QR code for more information

my.molnlycke.com

*Harding K, et al. Simplifying venous leg ulcer management. Consensus recommendations. Wounds International 2015.

1. Van Overschelde, P. et al. A randomised controlled trial comparing two wound dressings used after elective hip and knee arthroplasty. Poster presentation at 5th Congress of the WUWH, Florence, Italy, 2016. 2. Silverstein P. et al. An open, parallel, randomized, comparative, multicenter study to evaluate the cost-effectiveness, performance, tolerance, and safety of a silver-containing soft silicone foam. Journal of Burn Care and Research, 2011. 3. Gee Kee E.L. et al. Randomized controlled trial of three burns dressings for partial thickness burns in children. Burns, 2014. 4. David F. et al. A randomised, controlled, non-inferiority trial comparing the performance of a soft silicone-coated wound contact layer (Mepitel One) with a lipidocolloid wound contact layer (UrgoTul) in the treatment of acute wounds. International Wound Journal, 2017. 5. Patton M.L. et al. An open, prospective, randomized pilot investigation evaluating pain with the use of a soft silicone wound contact layer vs. staples on split thickness skin grafts as a primary dressing. Journal of burn care & research, 2013. 6. Bredow J. et al. Evaluation of Absorbent Versus Conventional Wound Dressing. A Randomized Controlled Study in Orthopedic Surgery. Deutsche Arzteblatt International, 2018. 7. Meaume S. et al. A study to compare a new self-adherent soft silicone dressing with a self-adherent polymer dressing in stage II pressure ulcers. Ostomy Wound Management, 2003. 8. Herst P. et al. Prophylactic use of Mepitel Film prevents radiation-induced moist desquamation in an intra-patient randomised controlled clinical trial of 78 breast cancer patients. Radiotherapy and Oncology, 2014. 9. Gotschall C.S. et al. Prospective, randomized study of the efficacy of Mepitel on children with partial-thickness scalds. Journal of Burn Care & Rehabilitation, 1998.

Find out more at www.molnlycke.com

Molnlycke Health Care AB, P.O. Box 6, Entreprenörstråket 21, SE-43153 Mölndal, Sweden. Phone +46 31 722 30 00. The Molnlycke, Epaderm, Exufiber, Granudacyn, Granulox, Mepilex, Mepitel, Mextra, Safetac and Tubifast trademarks, names and logos are registered globally to one or more of the Molnlycke Health Care Group of Companies. Mepi is a trademark of Molnlycke Health Care. © 2025 Molnlycke Health Care AB. All rights reserved. HQ1M006997 - CAD 2025

